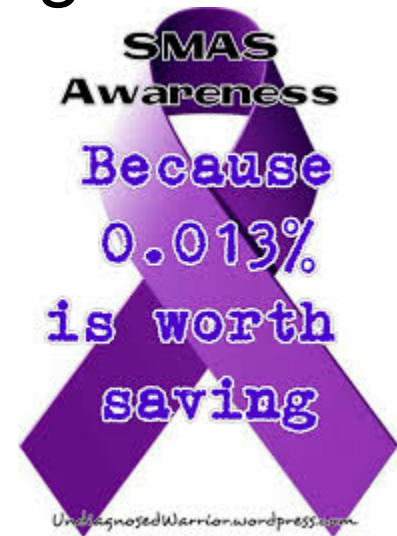



SUPERIOR MESENTERIC SYNDROME

Liz Sim



CASE PRESENTATION

- 34 yom with PMHx schizoaffective disorder presents with nausea, vomiting, abdominal pain.
 - Admits to weight loss
 - Decreased food intake
- PSHx appendectomy



CASE PRESENTATION

○ Exam

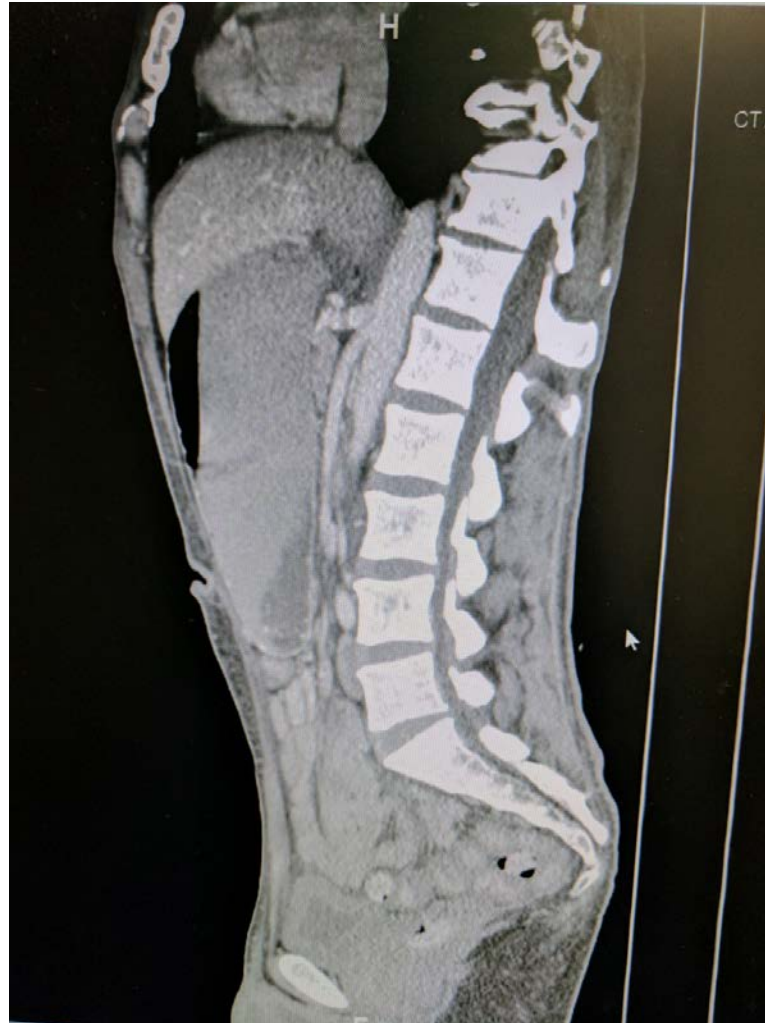- 98.7 F 95/61 90 18 96%
- NAD, thin BMI 19
- Abdomen flat, ND, NT

○ Labs

- Hypokalemic to 3.1
- Albumin 4.9



CTAP



OPERATIVE COURSE

- Exploratory laparotomy, gastrojejunostomy

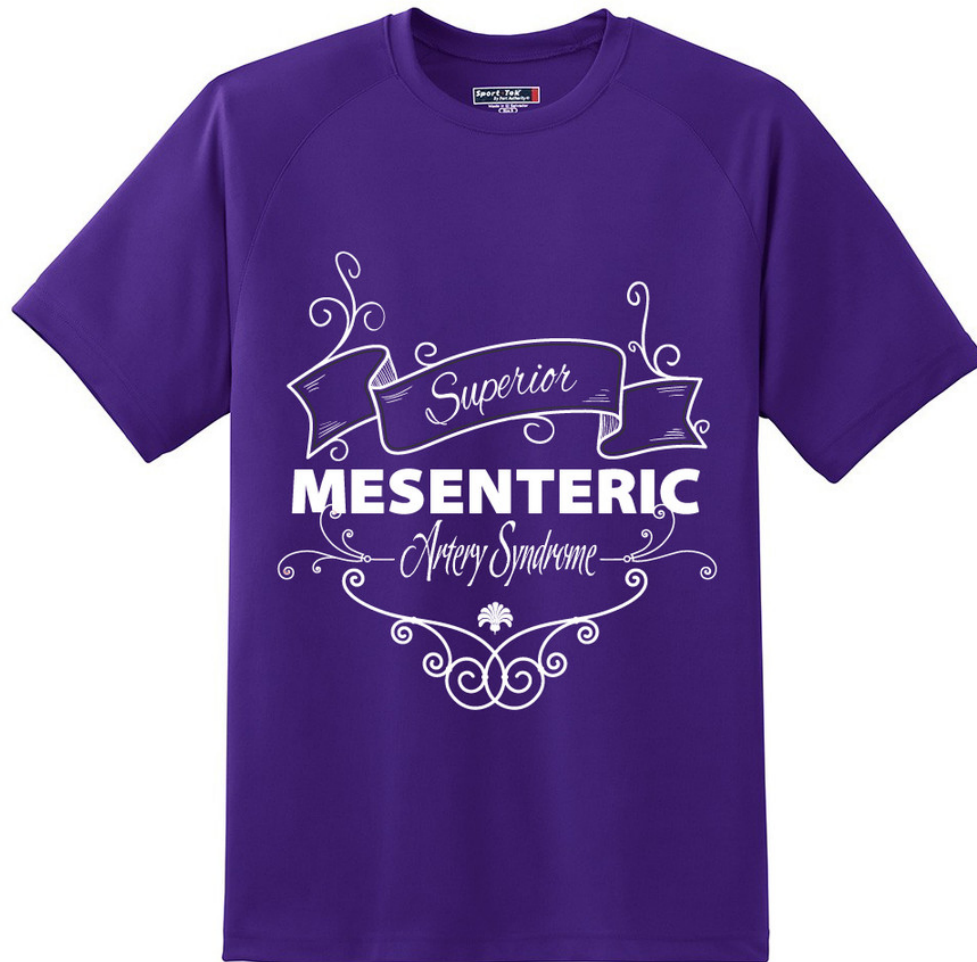

POST OPERATIVE COURSE

- NGT removed POD 1 and CLD started
- DC home POD 3
- Followed up in clinic with no complaints



QUESTIONS?



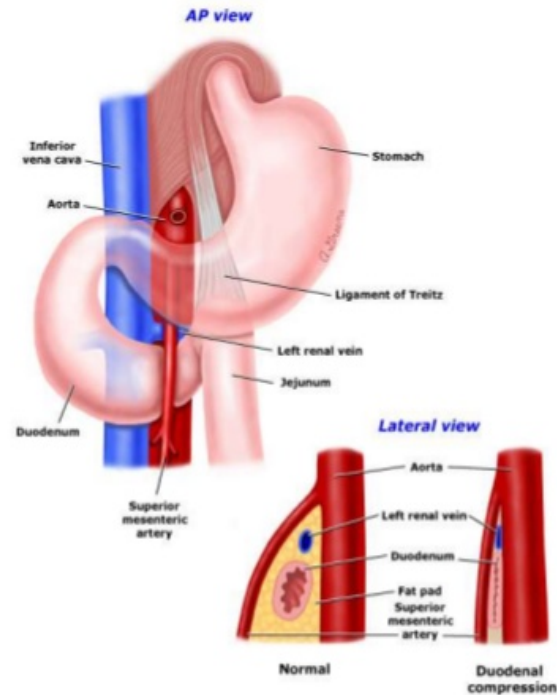
SMA SYNDROME

- Superior mesenteric artery (SMA) syndrome
 - Wilkie's syndrome, arterio-mesenteric duodenal compression syndrome, the cast syndrome and chronic duodenal ileus
- Incidence between 0.013% and 0.3%.
- Young female adults aged between 17-39 years old
 - Rapid weight loss, immobilization in the supine position, body casts, malrotation or paraduodenal hernias and abdominal aorta aneurysm



WHAT IS IT?

- Entrapment of the third part of the duodenum between the aorta and the SMA.
- Normal angle is 38° and 65°
- Reduced to less than 20° causing gastric outlet obstruction
- Length and attachment of Treiz influences the angle



PRESENTATION

- Malnourished, low BMI
- Obstructive symptoms
 - Early satiety, belching, post prandial pain



WORK UP

- Maneuvers alleviate symptoms
 - Knee to chest
 - Left decubitus
 - Hayes maneuver
- Barium swallow
 - obstruction of the third part of the duodenum with proximal dilation
 - Delay of 4-6 hours of contrast
- CTAP
 - Measure the angle



TREATMENT

- Medical
 - Uncomplicated cases: short history, moderate symptoms and incomplete duodenal obstruction
- Repletion of electrolytes
- Weight gain
 - Small, frequent, high calorie meals
 - Feeding tube past the obstruction
 - Some advocate TPN



TREATMENT

- Surgery
 - Duodenojejunostomy
 - >90% success
 - Gastrojejunostomy
 - blind loop syndrome
 - persistence of symptoms due to the non-decompression of the duodenum.
 - Division of the ligament of Treitz
 - Typically reserved for infants
 - recurrence rate that may be up to 25%



REFERENCES

- Yehya Khodea, Wisam Al-Rami, Zsolt Bodnar. Laparoscopic management of a complicated case of Wilkies Syndrome: A case report. *International Journal of Surgery Case Reports*. 2017; 37 (1) 177-179
- Lorentziadis, Michael. Wilke's syndrome. A rare cause of duodenal obstruction. *Annals of Gastroenterology*. 2011; 24(1) 59-61
- Brian Pottorf, Farah Husain, H Whitton Hollis Jr. Laparoscopic Managament of Doudenal obstruction resulting from Superior mesenteric artery syndrome. *JAMA Surg*, 2014; 149(12):1319-1322
- Ulises Baltazar, Julie Dunn, Carlos Floresguerra et al. Superior Mesenteric Artery Syndrom: An uncommon cause of intestinal obstruction. *Southern Medical Journal*. 2000;96 (6)606-609

