Lidie Lajoie, MD MSc
SUNY Downstate Surgery Grand Rounds
June 23, 2011

Endoscopic-Assisted Laparoscopic Duodenal Polypectomy

LECS: Emerging Technology

- Duodenal Neoplasms
- Overview of LECS procedures
- Case Presentation
- Video
- Discussion

Duodenal Neoplasms

- Most commonly benign adenomas
- Primary malignancy rare:
  - adenocarcinoma (35-50%)
    - 45% villous adenomas undergo malignant degeneration
    - Risk factors include smoked/cured meats, Crohns, Celiac, HNPCC, FAP, Peutz-Jeghers
  - carcinoid (20-40%)
  - lymphoma (10-15%)
  - GIST (15%)

Duodenal Neoplasms

- Presentation:
  - asymptomatic until large
  - Gastric outlet obstruction
  - Bleeding/anemia
  - weight loss
  - jaundice
- Diagnosis:
  - 0.3-4.6% incidence of duodenal polyp on EGD.
  - Small bowel series or capsule endoscopy

Duodenal Neoplasms

- Treatment:
  - If symptoms or risk for malignant degeneration - endoscopic or surgical resection
- Outcomes:
  - Complete surgical resection of adenocarcinomas (50%) associated with 50-60% 5-year survival

Transgastric Endoluminal laparoscopic Surgery

Laparoscopic-Endoscopic Cooperative Approach (LECS)

Laparoscopic-Endoscopic Rendezvous Procedure

Endoscopic Resection under Laparoscopic Observation

LECS – what is it?

- Method of minimally-invasive resection of gastrointestinal lesions too large to be removed endoscopically (>2cm)

LECS – preoperative planning

- Patient selection:
  - must be able to undergo general anesthesia and pneumoperitoneum
- Pathologic selection:
  - successful resection of T1 No Mo tumors of stomach, small and large bowel have been described.
- Physician selection:
  - qualified laparoscopist + endoscopist team

LECS – basic steps

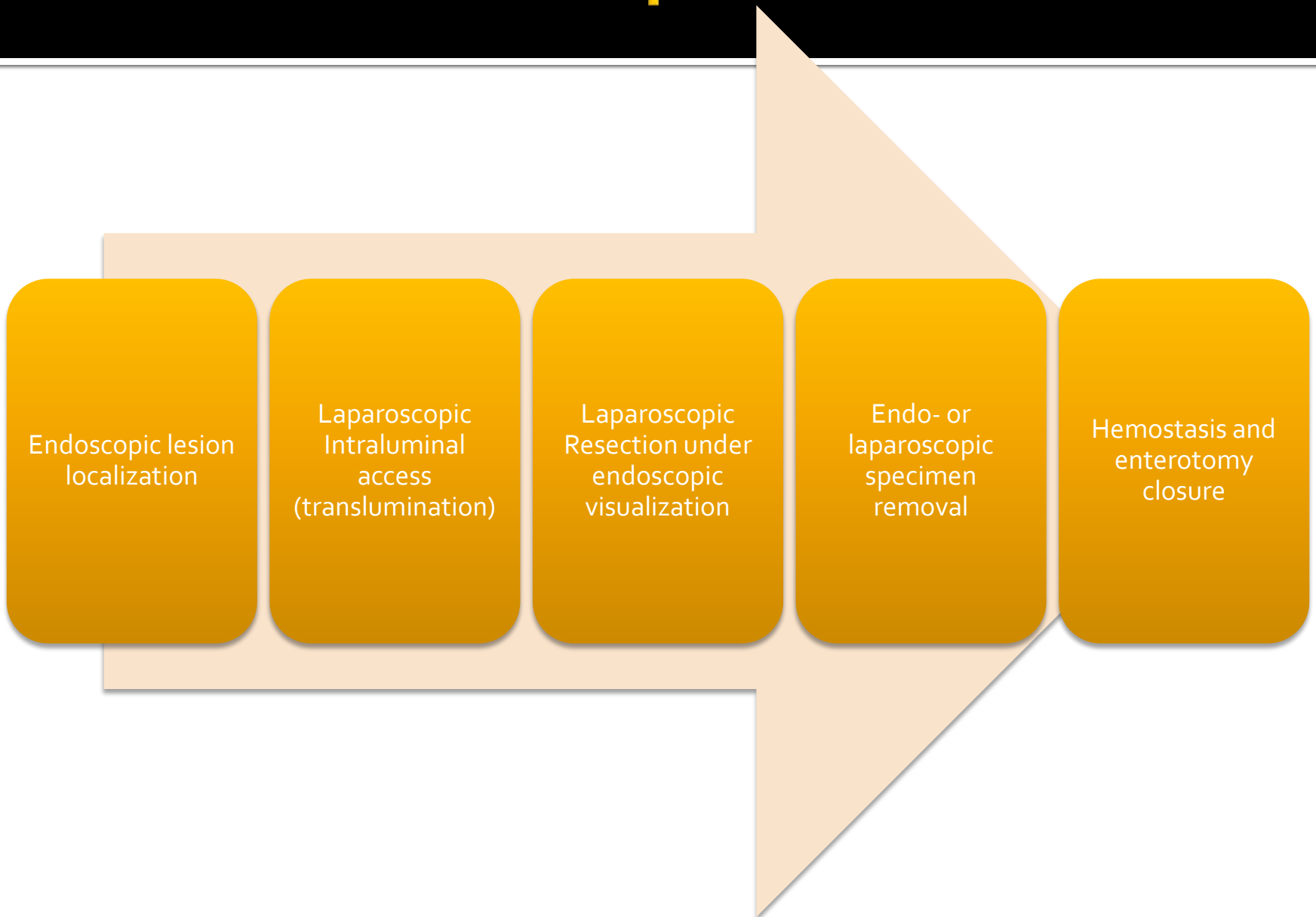

LECS - Results

- Few case reports and case series:
  - Gastric: <100 cases in few case series
  - Duodenal: < 10 cases reported
- Conversion to open surgery (5%)
- Complications (1%)
  - port site infections, hernias, cardiac events
- LOS: decreased vs open surgery, avg 5-6 days
- Recurrence (?): No more than 2-5yr follow up

Case Presentation

- 71yo F p/w anemia to PMD
- Large polyp in first portion of duodenum found on EGD
- Bx: hyperplastic polyp
- Referred to surgery for excision
- Preop CBC, BMP, coags wnl
- Scheduled for endoscopically assisted laparoscopic duodenal polypectomy

Operative Setup

- Supine position, arms tucked
- General anesthesia
- Endoscopist & monitors at head of table
- 5mm Optiview trocar in LUQ, insufflated to 15mmHg
- EGD to visualize lesion
- Transluminal trocar placement w/ endoscopic guidance

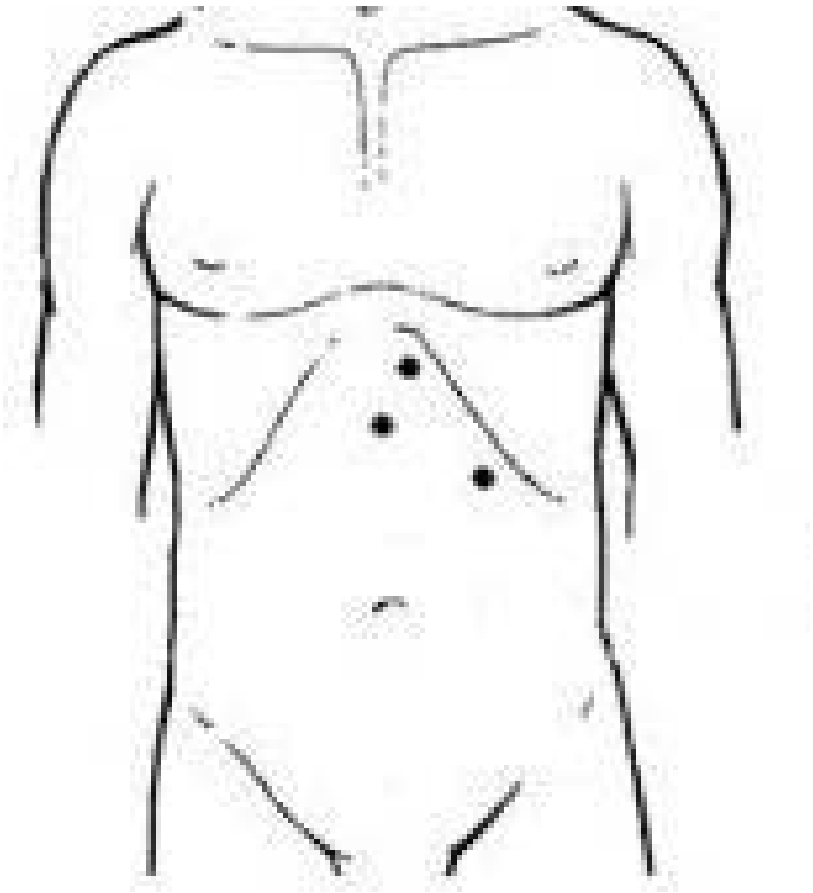

Procedure

Operative Findings

- 2 x 2.5 x 2 cm mixed hyperplastic and adenomatous polyp. Margins of resection free of dysplasia

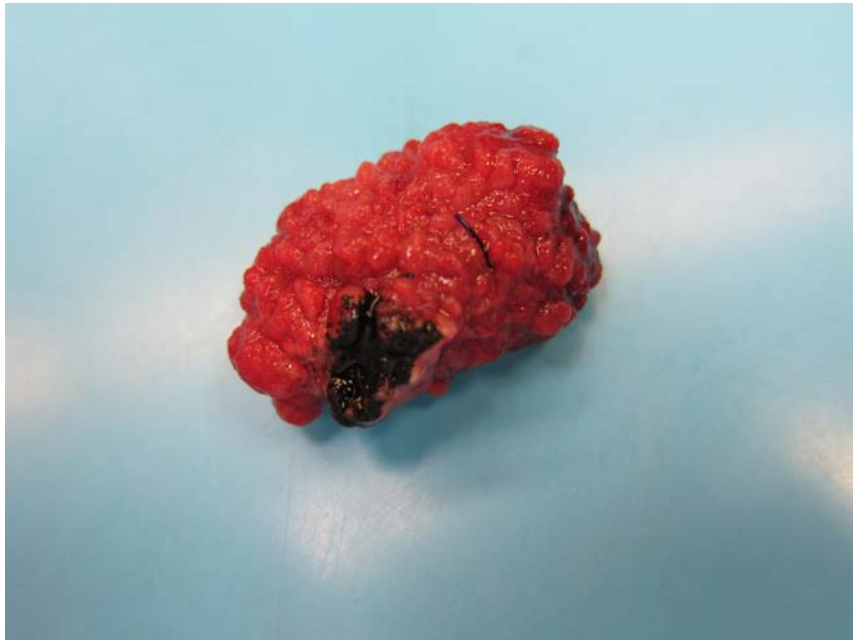

- Postop course: diet advanced & discharged home without event POD# 5