www.downstatesurgery.org

Penetrating Cardiac Injury

Getting to the Heart of the Matter

Marilyn Ng, MD

Dept. of Surgery Conference
Downstate Medical Center
Aug 11, 2011

SUNY DOWNSTATE Medical Center

Richmond University Medical Center

Case Presentation

- 28 yo M with unknown PMHx
- Level 1 notification from ED
- Single stab wound (SW)
- Left parasternal SW at 5th ICS

EMS Handoff

- Unknown downtime & anoxic time
- Unobtainable vital signs at scene
- Pt arrives in extremis
- Pulseless and in asystole

Physical Exam

- Vitals signs not obtained
- Airway: Intubated; agonal breaths
- Breathing: Ambu-bag by RT
- Circulation: No pulses
  - CPR initiated; PIV epinephrine
  - Peripheral lines & central line placed
  - Rapid infusion: 4 L IVF & 2 PRBC

Physical Exam

- GCS 3
- HEENT: NCAT, pupils fixed dilated
- CV: asystole, no pulses
- Lungs: BS bilaterally
- Chest: single SW to left chest
- Abd: soft, NT, ND, no rigidity
- FAST exam: no abdominal free fluid

ED Labs after EDT

- CBC: 8>13/40.7<193
- BMP: 146/5.5/106/20/9.8/1.2<167
- LFT: 7.1/3.9/29/20/48/0.7
- PT/PTT/INR: 12.5/22.9/1.18
- ABG: 7.38/41/320/-3.9/99

ED Thoracotomy

- No blood in left thorax
- Pericardiotomy
  - Evacuation of ~ 1 liter hemopericardium
- Cardiac massage performed
- Laceration in right ventricle

www.downstatesurgery.org

ED Thoracotomy

- SW oversewn with 0 Prolene
- Intracardiac epinephrine
- Ventricle fibrillation
- Internal cardiac defibrillation
  - BP 132 / 93 and HR 42

www.downstatesurgery.org

Cardiac Injury

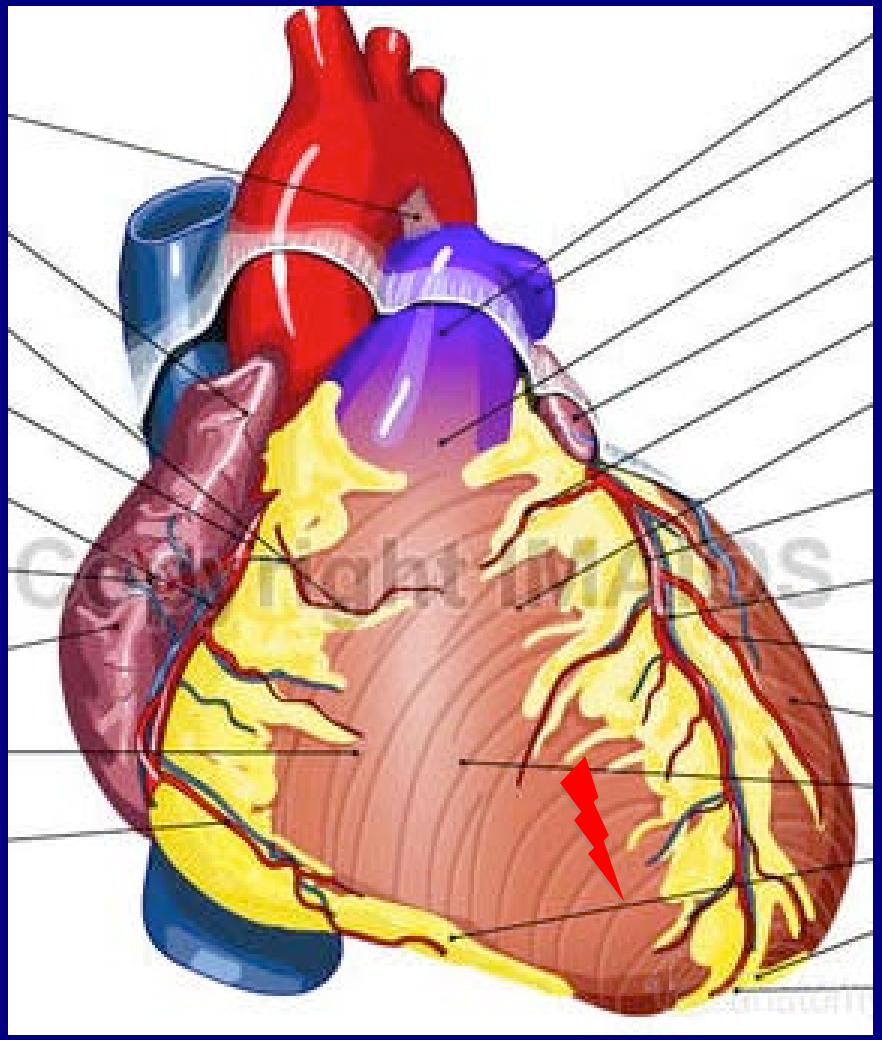

www.downstatesurgery.org

OR Video

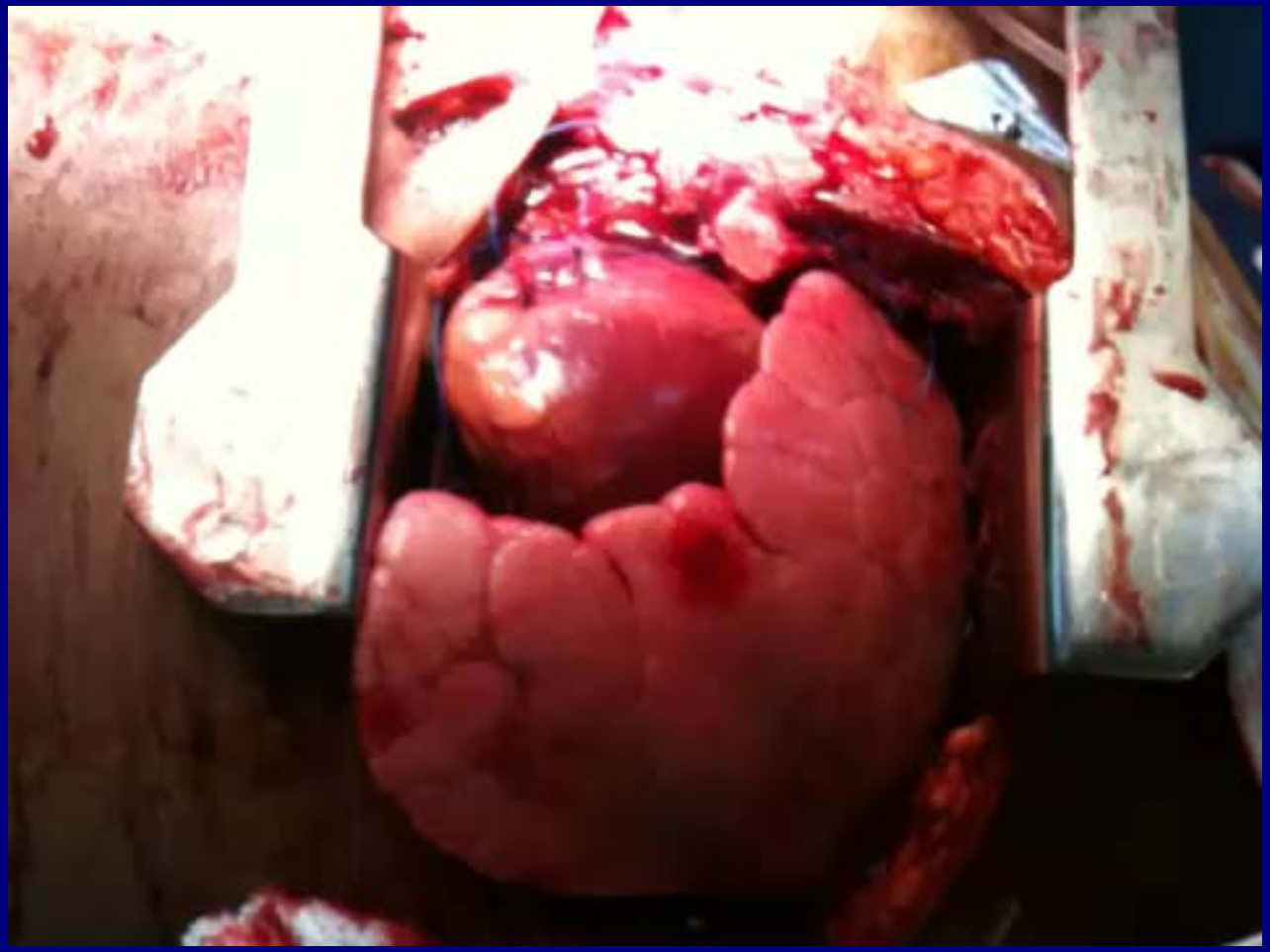

Operative Procedure

- Intra-operative thoracic consult
- Thoracotomy irrigation
- LUL laceration (2 cm) repair
- No posterior cardiac injury
- SW exploration – no abdominal component

Operative Procedure

- Pericardiotomy partial closure
- 32F chest tube placed
- Thoracotomy closure
- Operative time ~ 3.5 hrs
- IVF 10 L, 10 PRBC, 2 FFP; EBL 2 L

Post - Op Course

- **POD#1:**
  - **Ancef given 48 hrs post-op**
  - **Myoclonus – pin-point pupils**
  - **CT Head and C-spine – negative**
  - **Coagulopathy reversed (INR 2.83)**
- **POD#2: Anti-epileptics**

www.downstatesurgery.org

Post - Op Course

- POD#3:

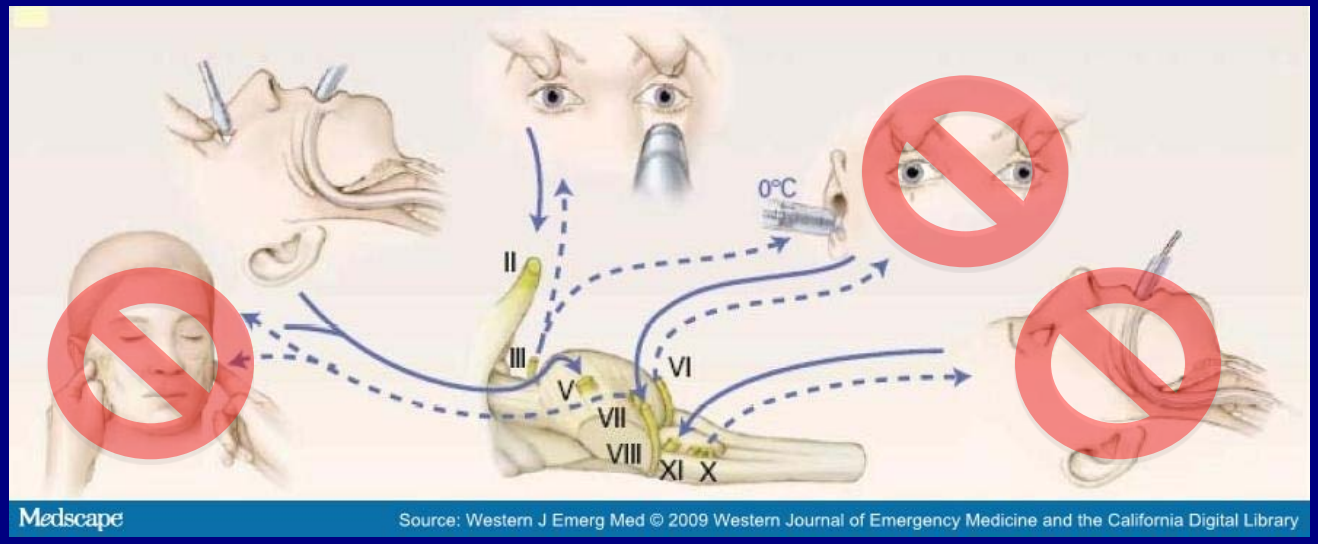

  - Echo negative

- POD#4: EEG; Enteral nutrition

Post - Op Course

- **POD#5:**
  - **Heparin DVT ppx started**
  - **Febrile to 101.6**
  - **Evolving hypoxic injury bilateral BG**
- **POD#6:**
  - **Broad-spectrum antibiotics started**
  - **Duplex (-) bilateral LE & Echo (-)**

Post - Op Course

- POD#7: Bronchoscopy; BAL culture pseudomonas (+); LLL pneumonia
- POD#9: S/P tracheostomy
- POD#10: ARDS
- POD#11: Pt expired; ME case

Penetrating Cardiac Injury

- **Incidence: 0.16%**
- **Etiology**
  - **Gunshot wounds (63%)**
  - **Stab wounds (36%)**
  - **Impalement**
  - **Iatrogenic**

Asensio et al. *J Am Coll Surg* 1998

Historical Perspective

- 1829 Larrey - 1st successful pericardiocentesis
- 1874 Schiff – 1st open cardiac massage



www.downstatesurgery.org

Cappelen vs. Rehn

- Norway, 1895
- 1st cardiorrhaphy, but pt died 3 days later



- Germany, 1896
- Successful repair of right ventricle fencing injury

Søreide & Søreide. *J Trauma* 2006; Rehn L. *Arch Klin Chir, 1897*

www.downstatesurgery.org

The Box

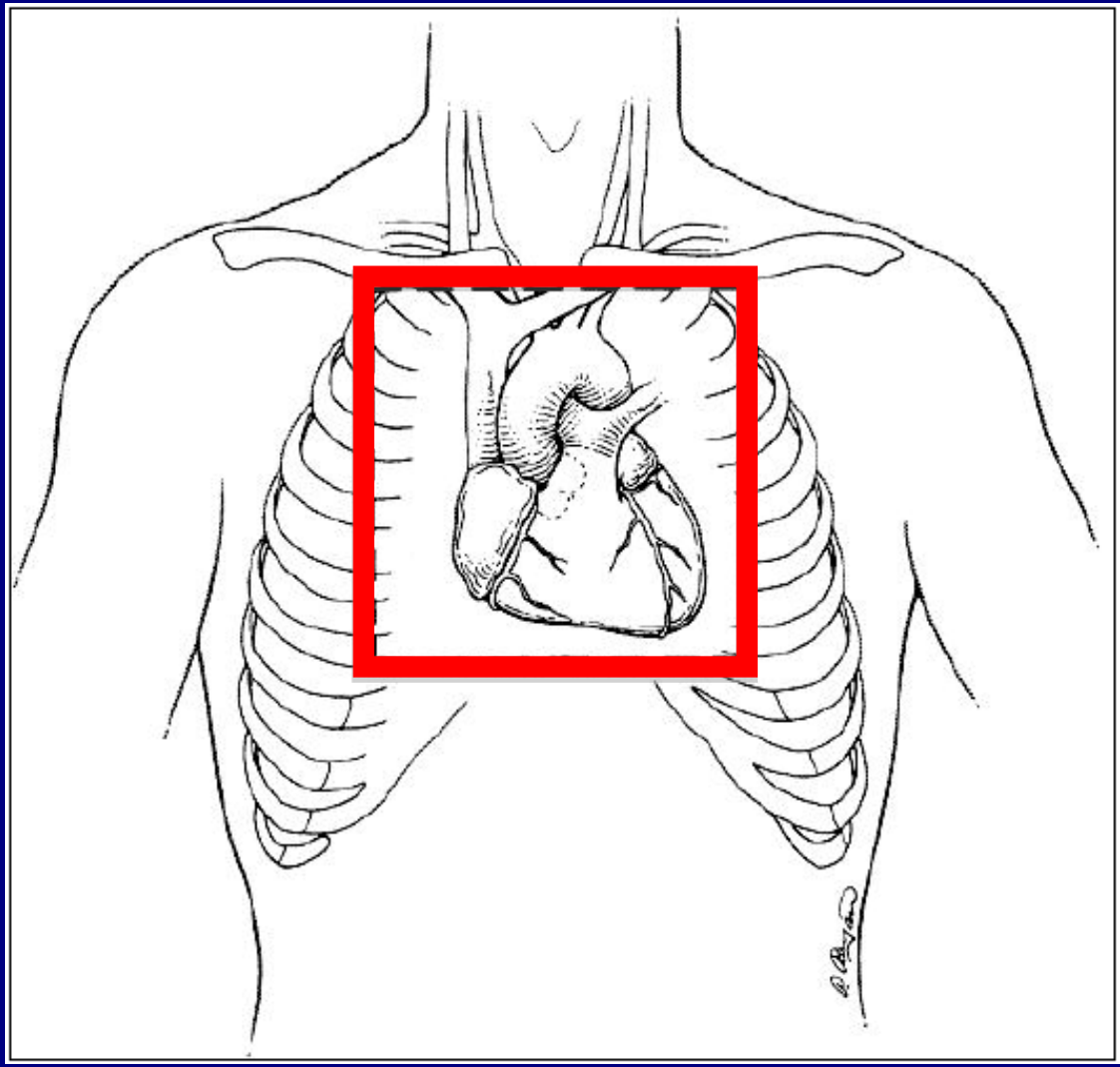

Pericardial Tamponade (PT)

- Beck's Triad (10%)
- Kussmaul's sign
- Protective effect ?
  - Survival: 73% with PT vs. 11% without PT
  - Regardless of mechanism

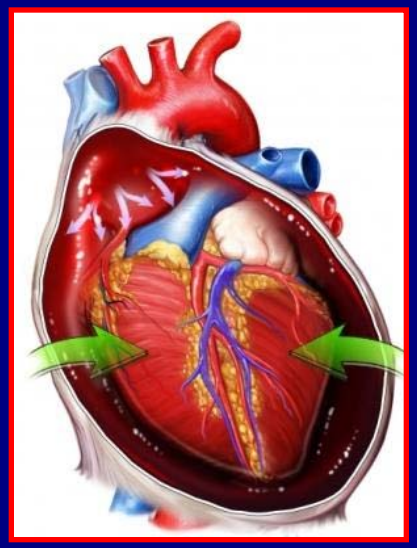

Moreno C, et al. *J Trauma,1986*

Penetrating Cardiac Injury

- **Mortality: 70-80%**
- **Site of cardiac injury**
  - **Right > Left**

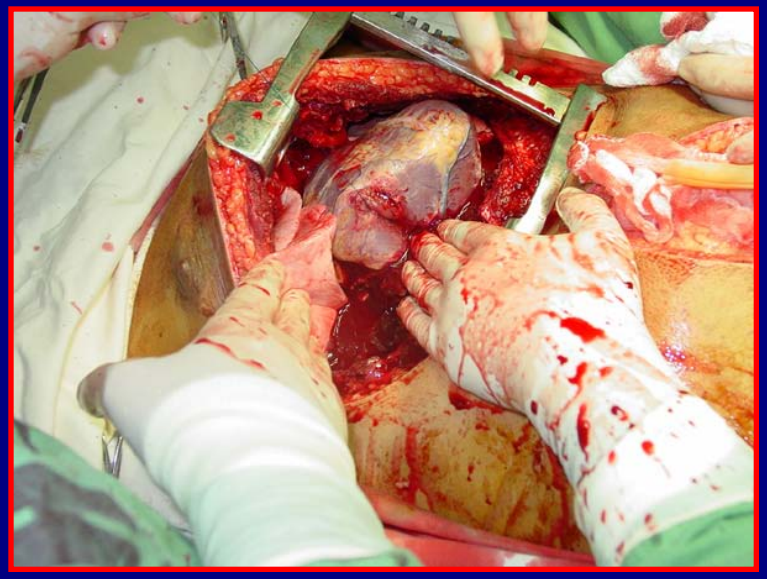

Feliciano et al *Trauma*, Ch 15

Role of Echocardiography

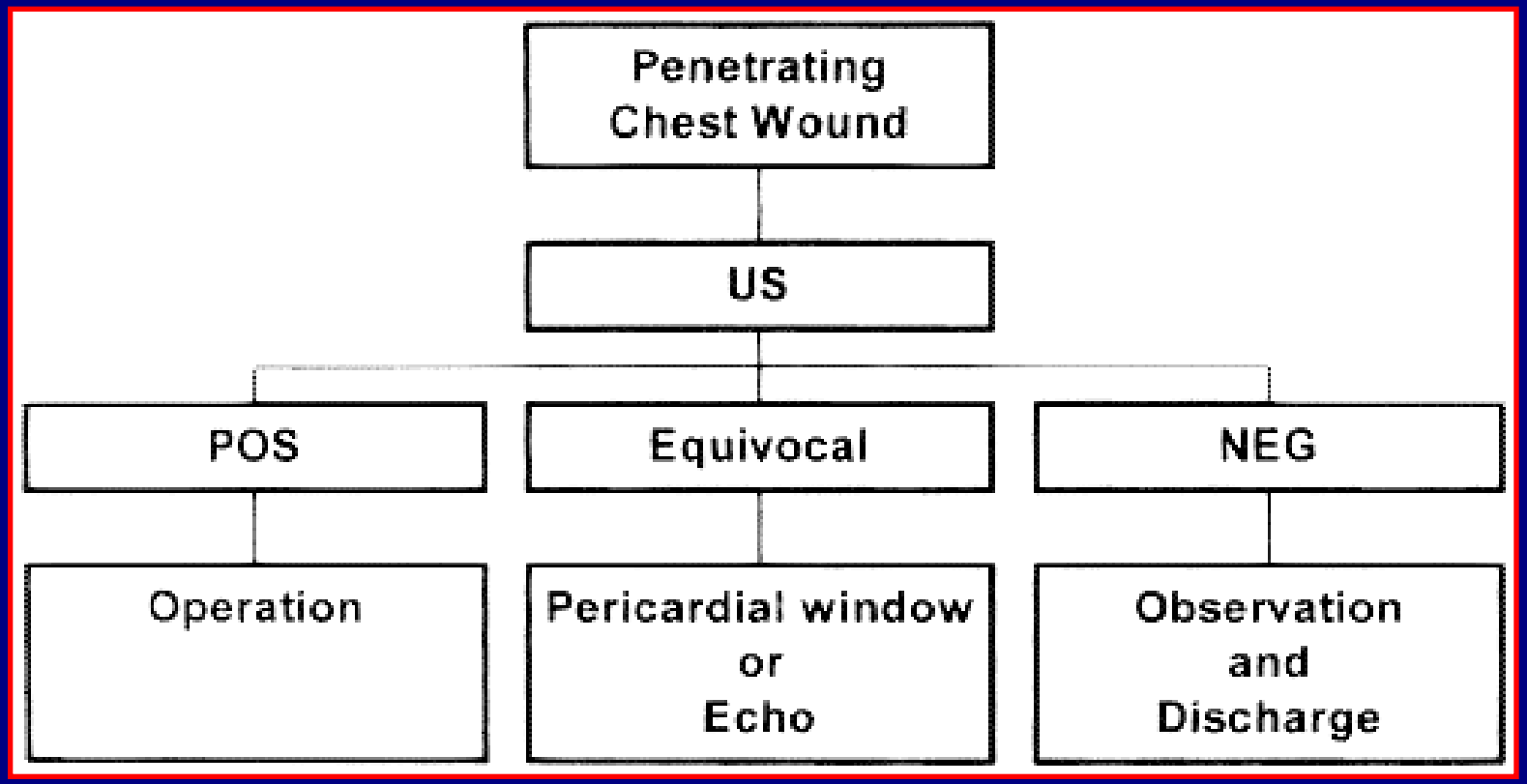

Rozycki et al, J Trauma, 1999

www.downstatesurgery.org

Echocardiography

Normal

Positive

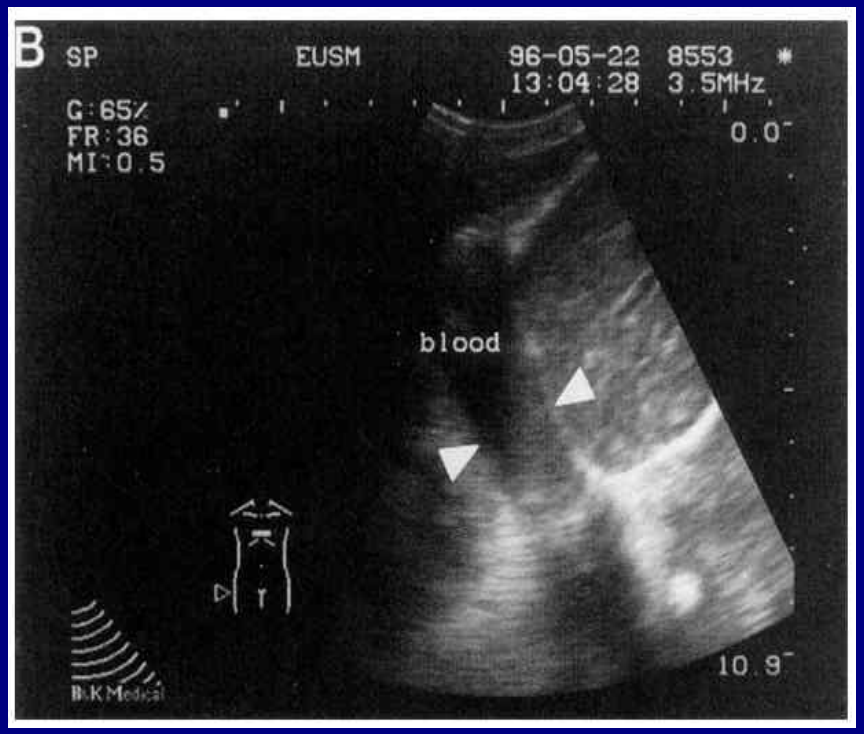

Rozycki et al, J Trauma, 1999

Non-Acute Management

- Pericardiocentesis
- Pericardial window
- Median sternotomy
- Thoracotomy

Feliciano et al *Trauma*, Ch 15

Pericardiocentesis

- No role in acute trauma
- Removal of 5-10 cc = ↑ CO by 25-50%
- Not sensitive or specific
  - False-negative = 80%
  - False-positive = 33%

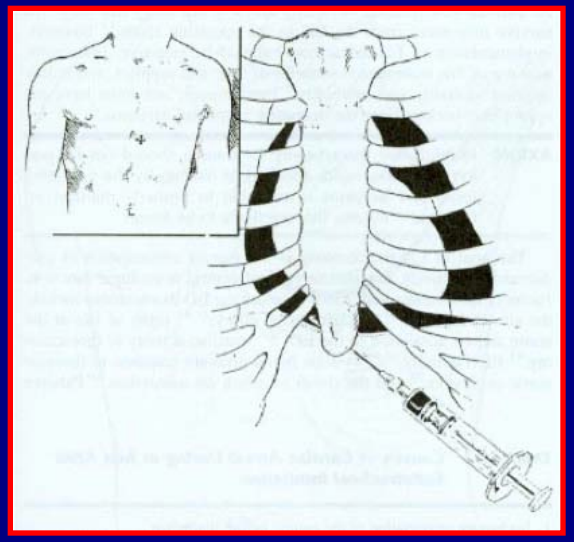

Demetriades et al, *Ann Surg*, 1985

ED Thoracotomy (EDT)

- **Thoracotomy performed in ED for pt arriving *in extremis***
  - **Cardiac tamponade & cardiac hemorrhage**
  - **Intrathoracic hemorrhage**
  - **Open cardiac massage**
  - **Thoracic aortic cross clamping**
  - **Evacuate air embolism**

www.downstatesurgery.org

ED Thoracotomy

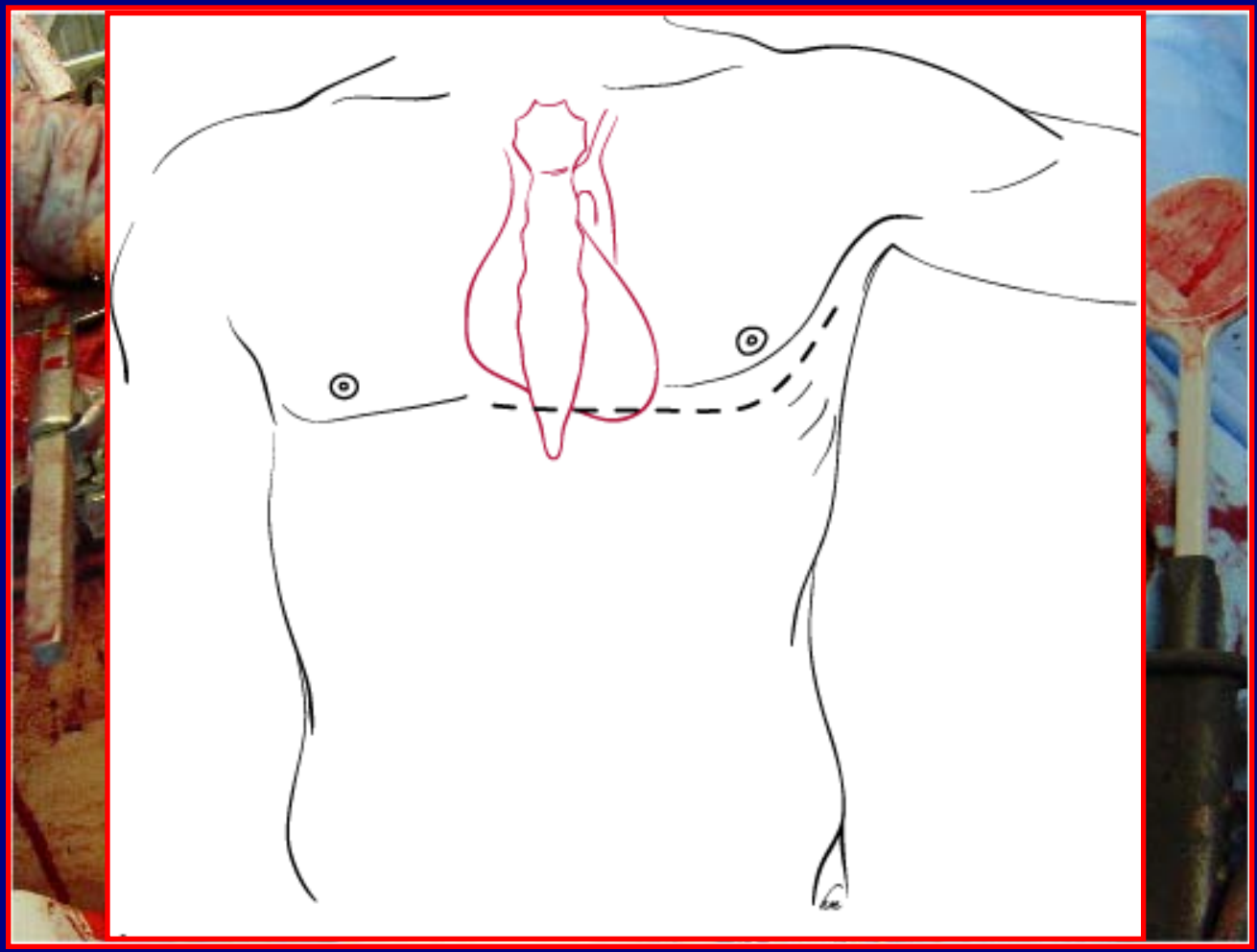

Feliciano et al. *Trauma*, Ch 15; Cothren CC and Moore EE*, World J of Emerg Surg* 2006.

Pericardial Window

- Hemodynamically "stable"
- Types
  - Sub-xiphoid
  - Intra-peritoneal
- Local vs. general anesthesia
- Diagnostic vs. therapeutic
- Problem: only 18% (+) for blood

Duncan A, et al. *J Trauma*, 1989

www.downstatesurgery.org

Pericardial Window

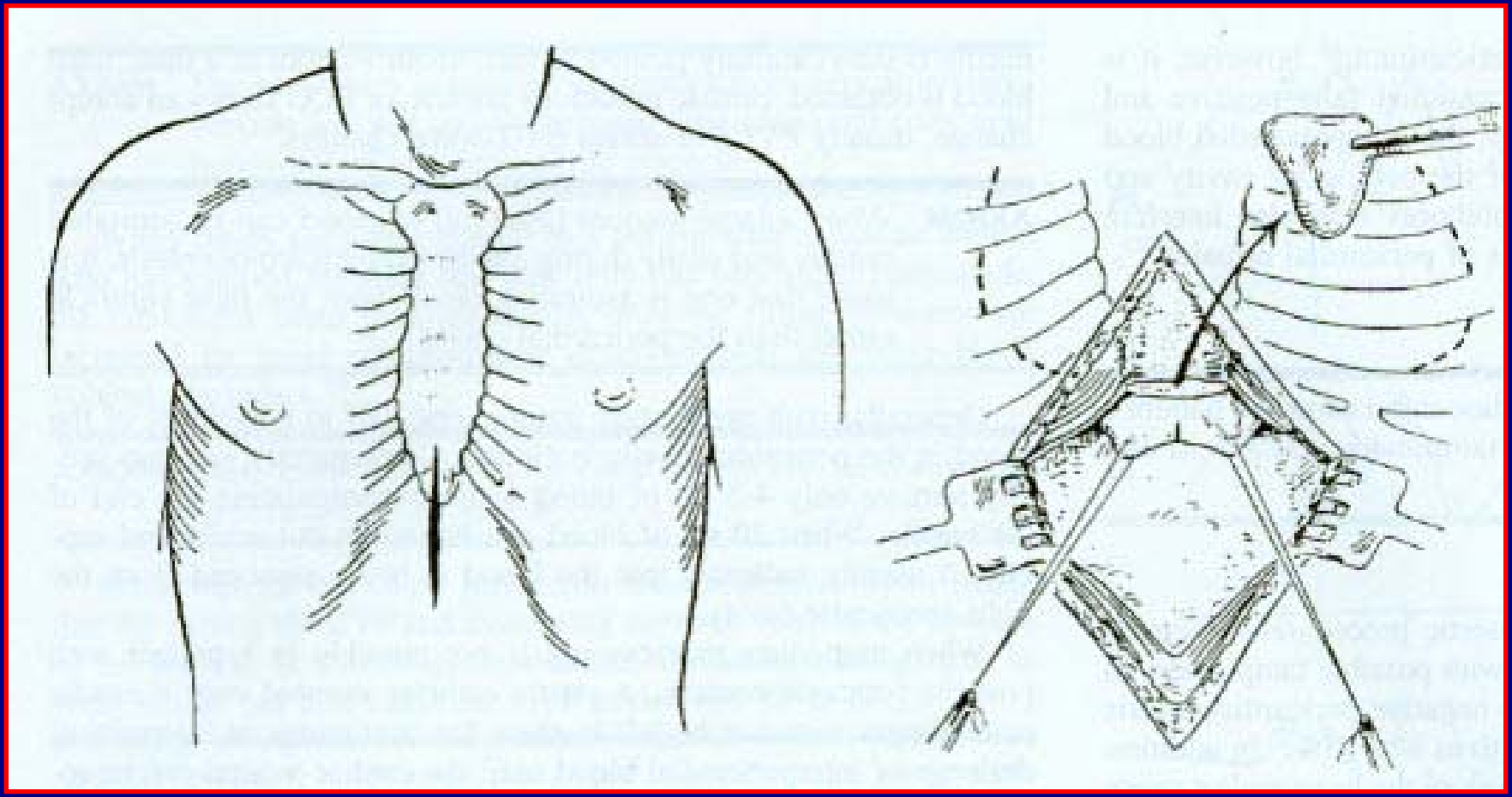

www.downstatesurgery.org

Anterior Injury

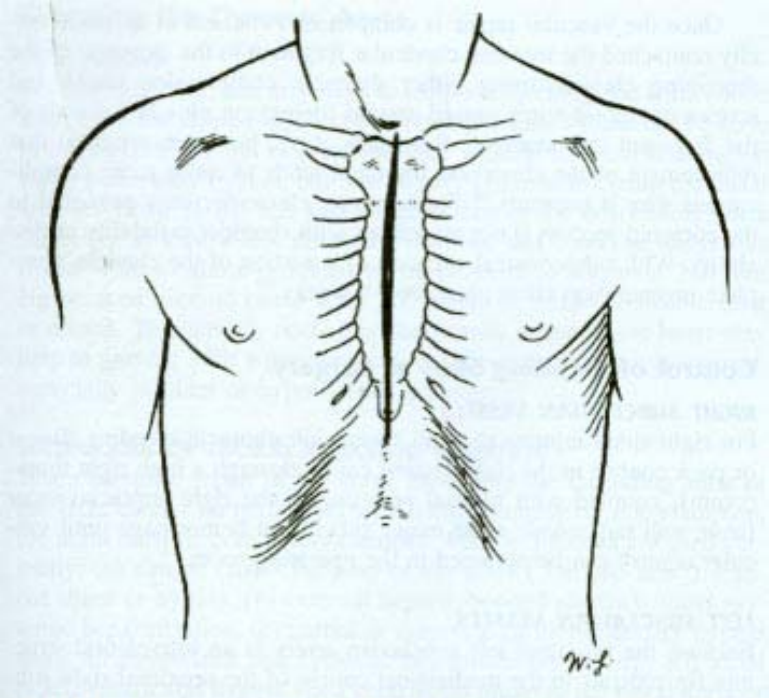

FIGURE 18–2 Median sternotomy. This incision is made from the top of the manubrium down past the xiphoid. The sternum is usually cut with a special electric saw after the soft tissue has been cleared from behind the superior and inferior borders of the sternum. This incision provides excellent exposure to the heart (especially anteriorly), to the ascending aorta, and to most of the aortic arch and its branches. The origin of the left subclavian artery may not be accessible through this incision in some patients. (From: Wilson RF. Injury to the heart and great vessels. Henning RJ, Grenvik A, eds. Critical care cardiology. New York: Churchill Livingstone, 1989; 442.)

- Classic approach
- "Quick & Easy"
- Used as an adjunct to modified approaches

Instability & Cardiac Injury

- Left thoracotomy – midline/left injury
- Right thoracotomy – right injury
- Clamshell – difficult exposure
- Thoracic aorta cross-clamping
  - 60% of cardiac output
  - Improve coronary/cerebral blood flow

www.downstatesurgery.org

Stapler

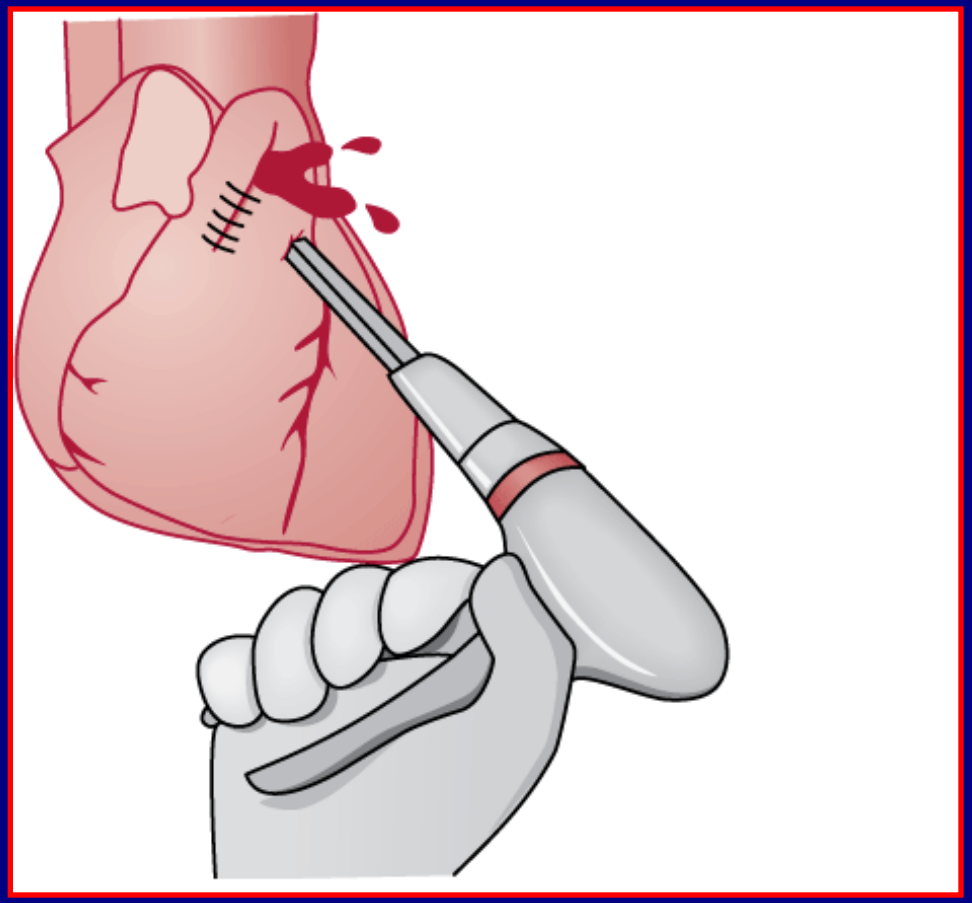

Macho et al. *J Trauma*, 1993

www.downstatesurgery.org

Right Atrial Injury

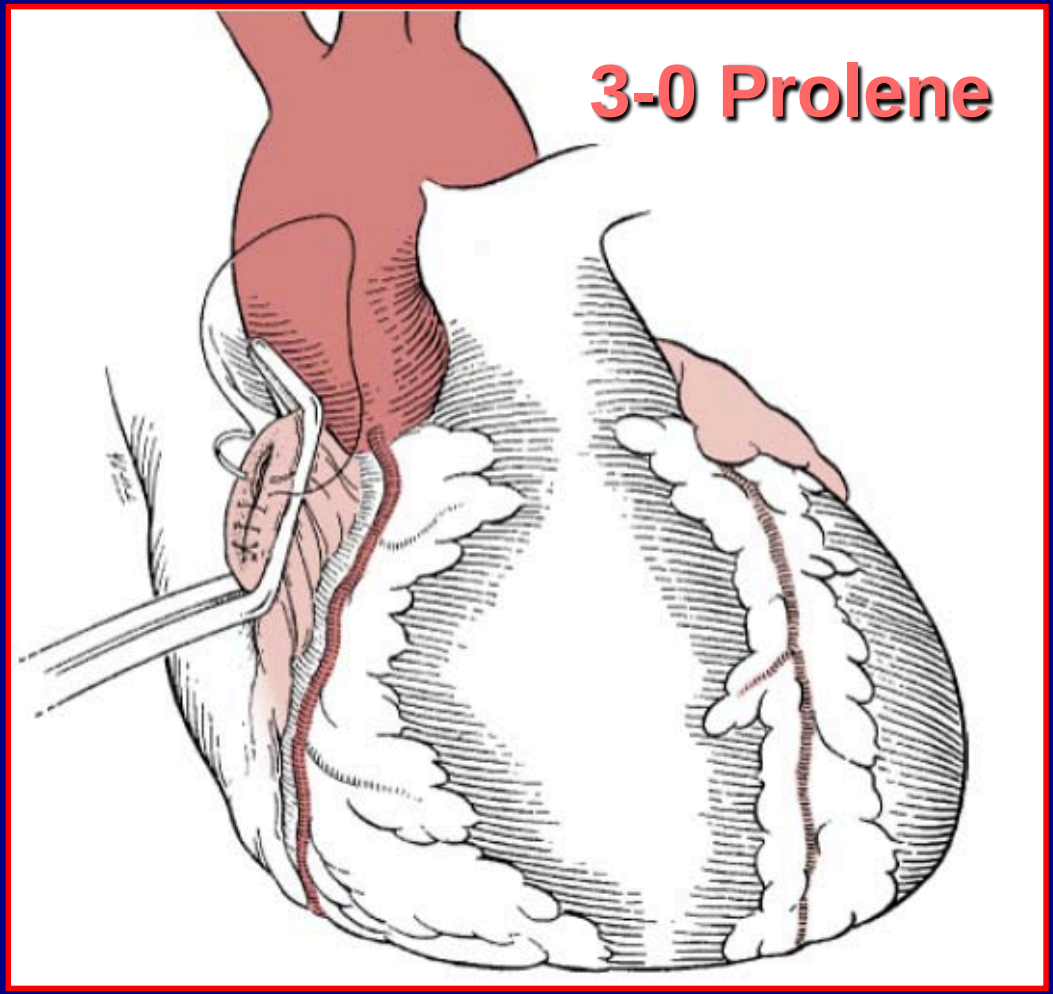

Feliciano et al. *Trauma*, Ch 15

Left Ventricular Injury

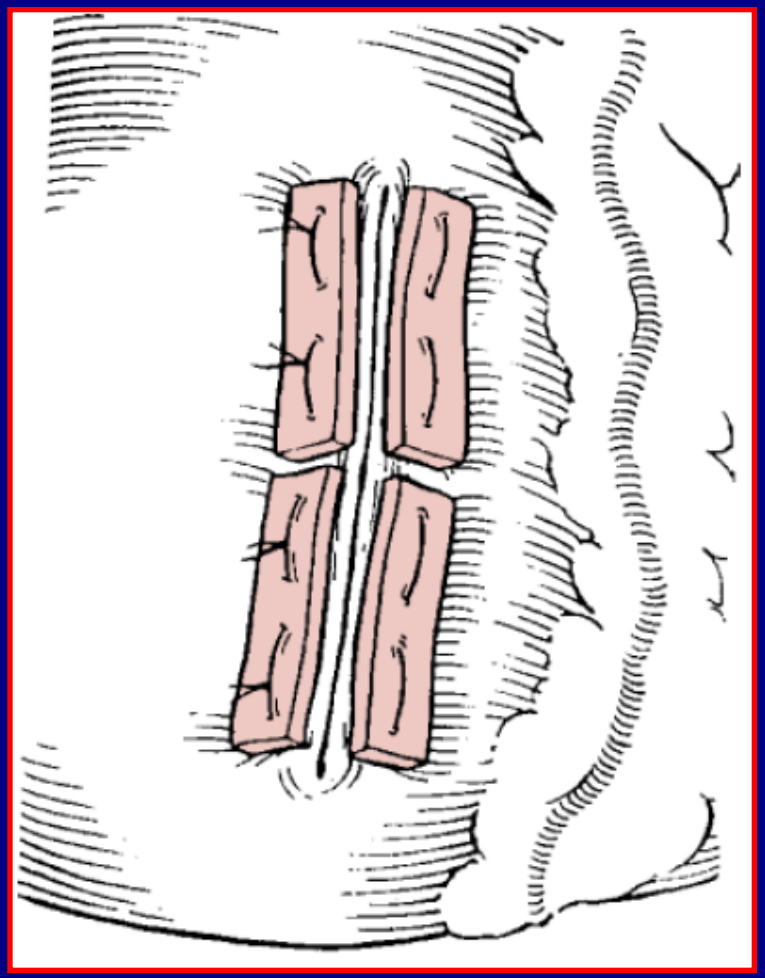

- 2-0 Silk / Prolene
- Pledgets
- Horizontal mattress sutures

Feliciano et al. *Trauma*, Ch 15

Injury by Coronary Vessels

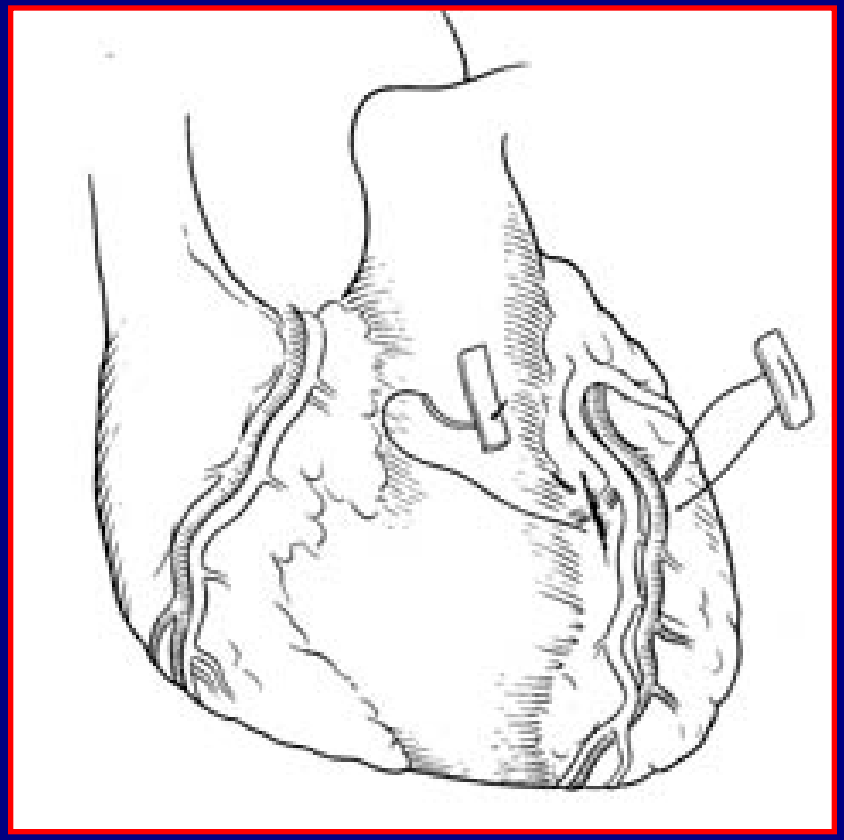

- LAD often injured
- Proximal coronary injury
  - Ligation if no cardiac dysfunction
  - Primary repair or bypass otherwise
- Ligation of distal coronary vessels

Feliciano et al. *Trauma*, Ch 15

Special Cardiac Injuries

Post - Operative Echocardiogram:

- Inter - ventricular ➔ delay repair
- Valves ➔ delay repair
- Ventricular aneurysms (left ventricle)

Survival Following EDT

Injury Pattern	Shock	No Vital Signs	No Signs of Life	Total
Cardiac	42/124 **(35%)**	47/254 **(19%)**	41/126 **(3%)**	96/612 **(16%)**
Penetrating	145/1007 **(14%)**	100/1252 **(8%)**	6/615 **(1%)**	283/2986 **(10%)**
Blunt	5/237 **(2%)**	4/377 **(1%)**	0/28 **(0%)**	11/790 **(1.4%)**

Table adapted from Branney et al. *J Trauma 1998*

www.downstatesurgery.org

Surviving Chest Trauma

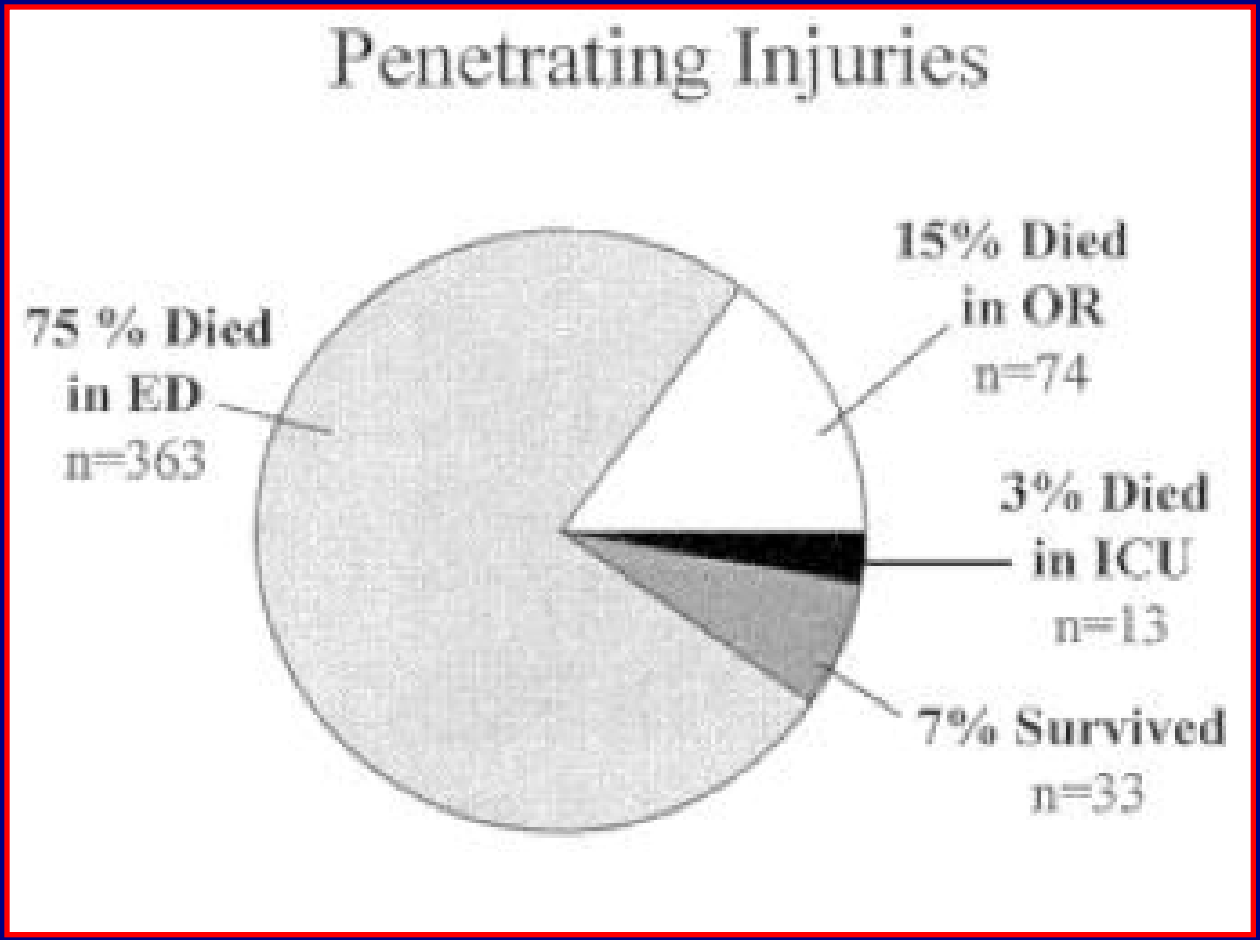

Branney et al. *J Trauma 1998*

Surviving the Mechanism

Mechanism	Total No.	Survivors		Neurologically Intact Survivors	
		n	%	n	%
Overall	868	41	5	34	4
Blunt	385	8	2	4	1
Penetrating	483	33	7	30	6
GSW	330	12	4	12	4
SW	147	21	14	18	12

Branney et al. *J Trauma 1998*

www.downstatesurgery.org

Vitals to Survival

Mechanism	With Vital Signs			Without Vital Signs			Sig[a]
	Total No.	Survivors		Total No.	Survivors		
		n	%		n	%	
Field							
Overall	243	23	10	624	12	2	$p = 0.01$
Blunt	126	4	3	269	0	0	$p = 0.02$
Penetrating	116	19	16	355	12	3	$p < 0.01$
GSW	73	9	12	255	3	1	
SW	4	10	23	100	9	9	
Emergency department							
Overall	160	21	13	708	14	2	$p < 0.001$
Blunt	86	3	4	311	1	0.3	$p = 0.19$
Penetrating	74	18	24	397	13	3	$p < 0.001$
GSW	42	6	14	286	5	2	
SW	32	12	38	111	8	7	

[a] Statistical significance of χ^2 comparison of patients with and without vital signs.

Branney et al. *J Trauma 1998*

Location of Chest Trauma

Mechanism and Site	Total No.	Survivors	
		n	%
Stab wounds			
Chest	109	20[a]	18
Abdomen	17	1	5
Head injury	1	0	
Other	5	0	
Gunshot wounds			
Chest	229	5	2
Abdomen	56	7	13
Head injury	11	0	
Other	19	0	

Branney et al. *J Trauma 1998*

www.downstatesurgery.org

Functional Survival

Mechanism and Anatomic Injury	Total No.	Survivors		Sig[a]
		n	%	
Stab wounds				
Cardiac tamponade	28	8[b]	29	6.56×10^{-5}
Penetrating cardiac	41	6[c]	15	0.01
Great vessel	21	0		
Hilar	13	2	15	
Lung	5	1	20	
Chest wall	10	3	33	0.04
Abdomen	18	1	5	
Head injury	1	0		
Other	6	0		
Gunshot wounds				
Cardiac tamponade	14	0		
Penetrating cardiac	112	2	2	
Great vessel	52	1	2	
Hilar	29	1	3	
Lung/chest	29	1	3	
Diaphragm	1	0		
Abdomen	58	7	12	0.009
Head injury	12	0		
Other	19	0		

Branney et al. *J Trauma 1998*

Conclusions

- Salvageable ?
- Most patients die before ED
- Pericardial tamponade protective
- Right ventricle commonly injured
- Greater survival with isolated cardiac injuries

References

- Emergency Department Thoracotomy. In: Feliciano DV, Mattox KL, Moore EE, eds. *Trauma*. 6th ed. New York, NY: McGraw-Hill; 2008:Chapter 15.
- Penetrating Cardiac Injury. In: Feliciano DV, Mattox KL, Moore EE, eds. *Trauma*. 6th ed. New York, NY: McGraw-Hill; 2008:Chapter 18.
- Rehn L: Ueber penetrerende herzwunden und herznaht. *Arch Klin Chir* 55:315, 1897.
- Asensio JA, Murray J, Demetriades D, et al.: Penetrating cardiac injuries: Prospective one year preliminary report; an analysis of variables predicting outcome. *J Am Coll Surg* 186:24, 1998

References

- Moreno C, Moore EE, Majure JA, et al.: Pericardial tamponade. A critical determinant for survival following penetrating cardiac wounds. *J Trauma* 26:821, 1986
- Rozycki GS et al: The role of ultrasound in patients with possible penetrating cardiac wounds: a prospective multicenter study. *J Trauma* 1999;46:543
- Duncan A, Scalea TM, Sclafani S, et al.: Evaluation of occult cardiac injuries using subxiphoid pericardial window. *J Trauma* 29:955, 1989
- Macho JR, Markison RE, Schecter WP: Cardiac stapling in the management of penetrating injuries of the heart: rapid control of hemorrhage and decreased risk of personal contamination. *J Trauma* 1993;34:711.)

References

- Cothren CCC and Moore EE. Emergency department thoracotomy for the critically injured patient: Objectives, indications, and outcomes. *World J Emerg Surg*. 2006 Mar;

- Branney SW, Moore EE, Feldhaus KM, Wolfe RE. Critical analysis of two decades of experience with postinjury emergency department thoracotomy in a regional trauma center. *J Trauma*. 1998 Jul;45(1):87-94; discussion 94-5.

www.downstatesurgery.org

Questions ?